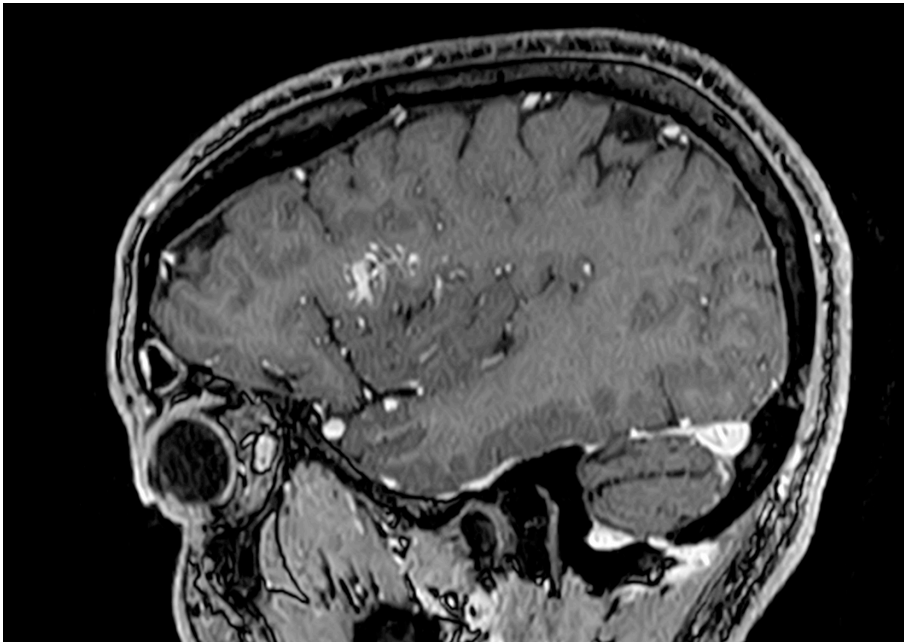
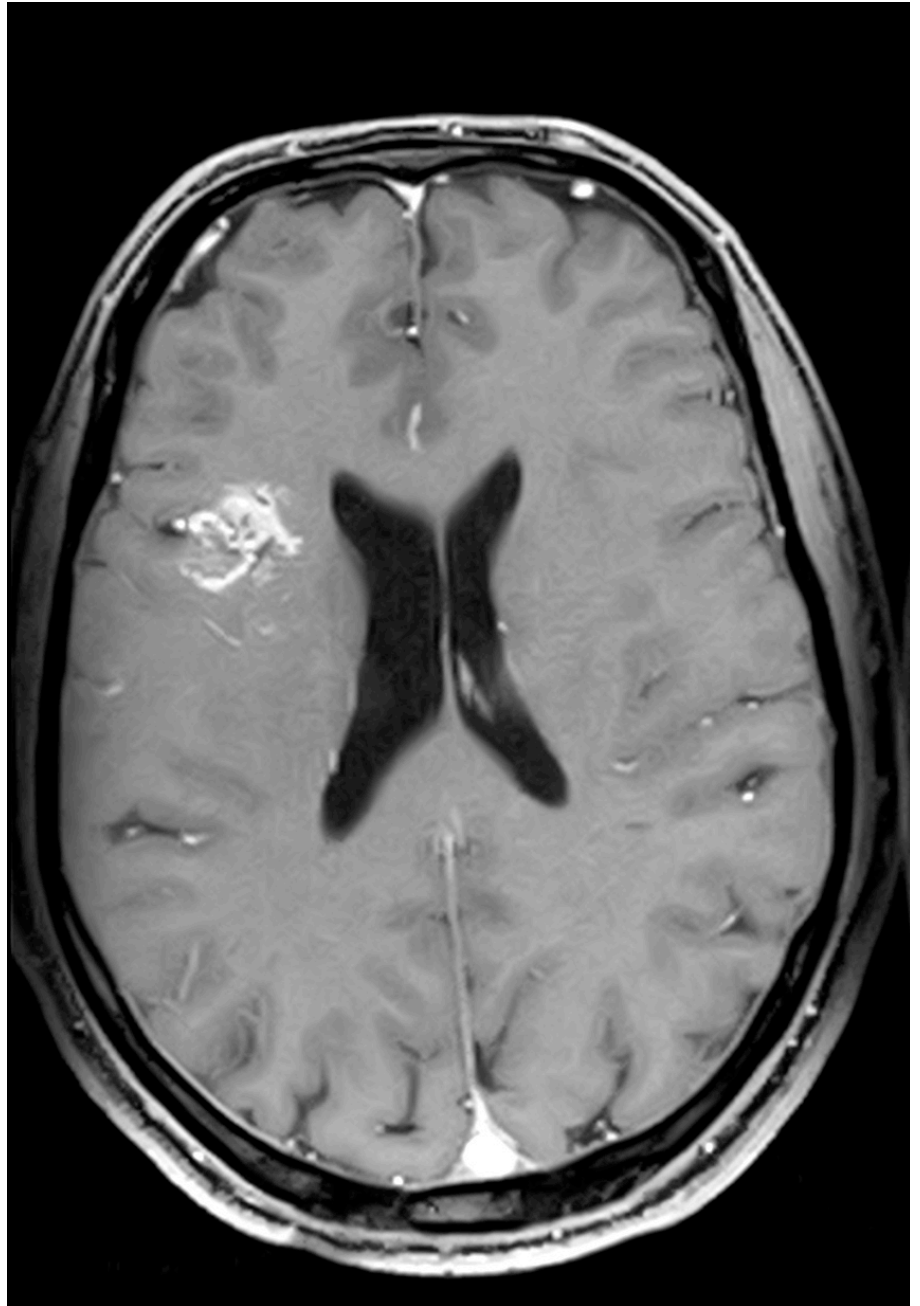
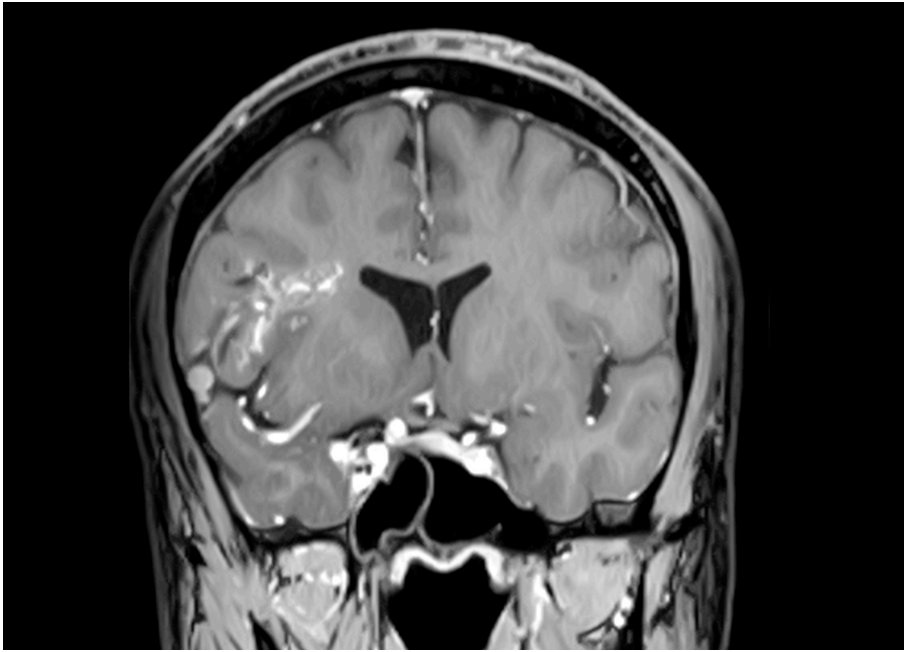
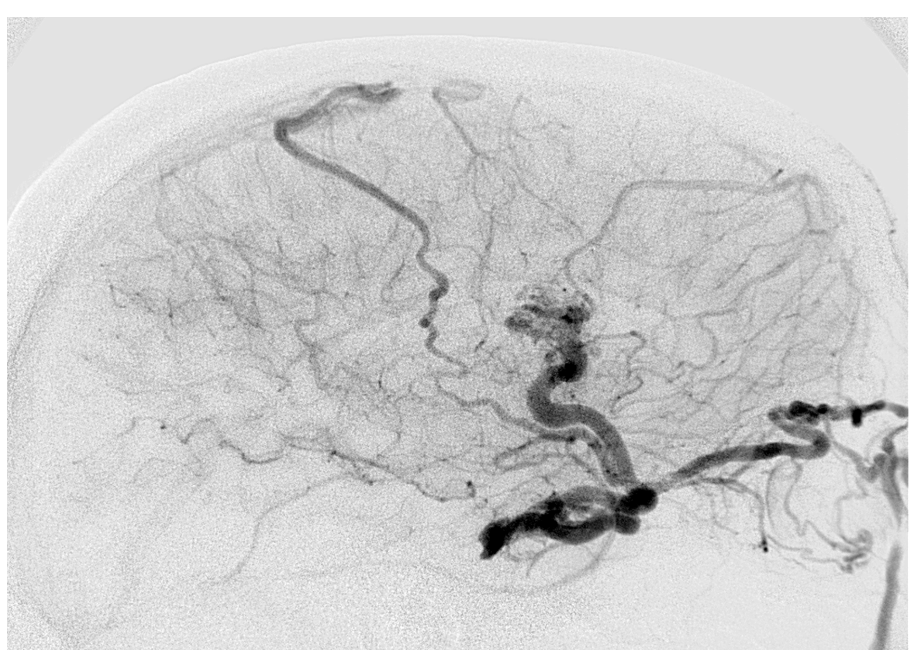
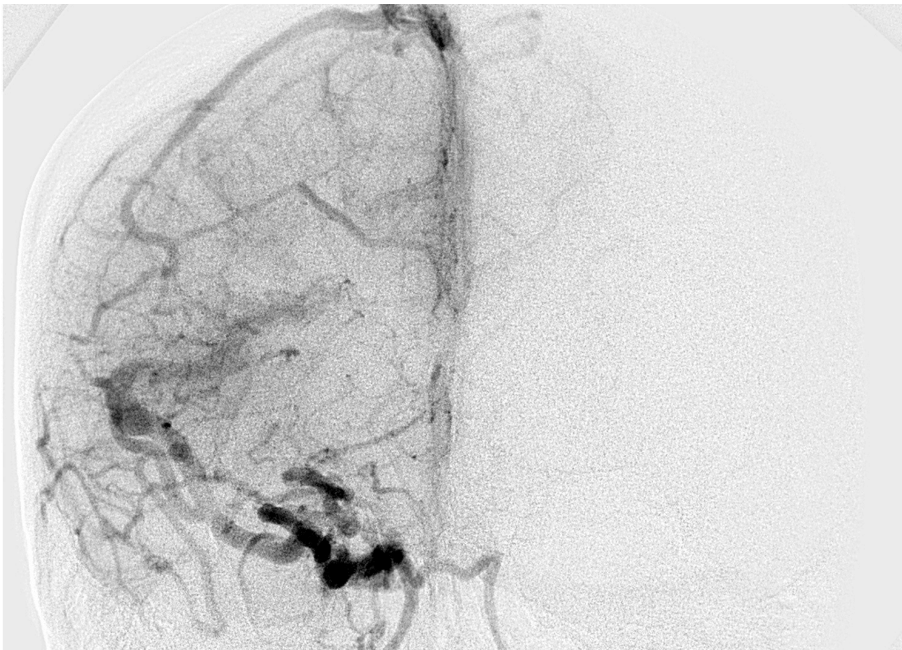
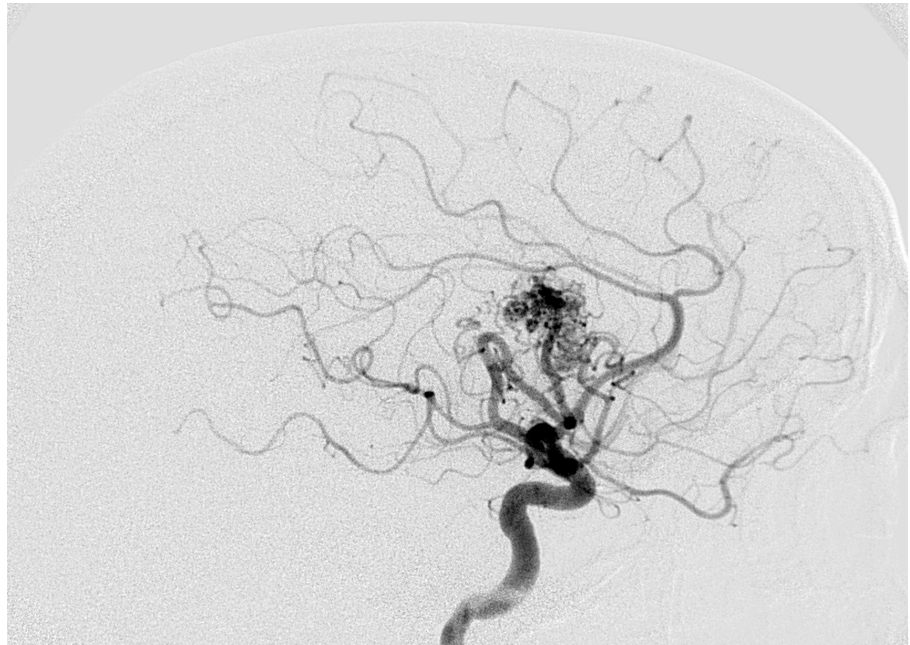
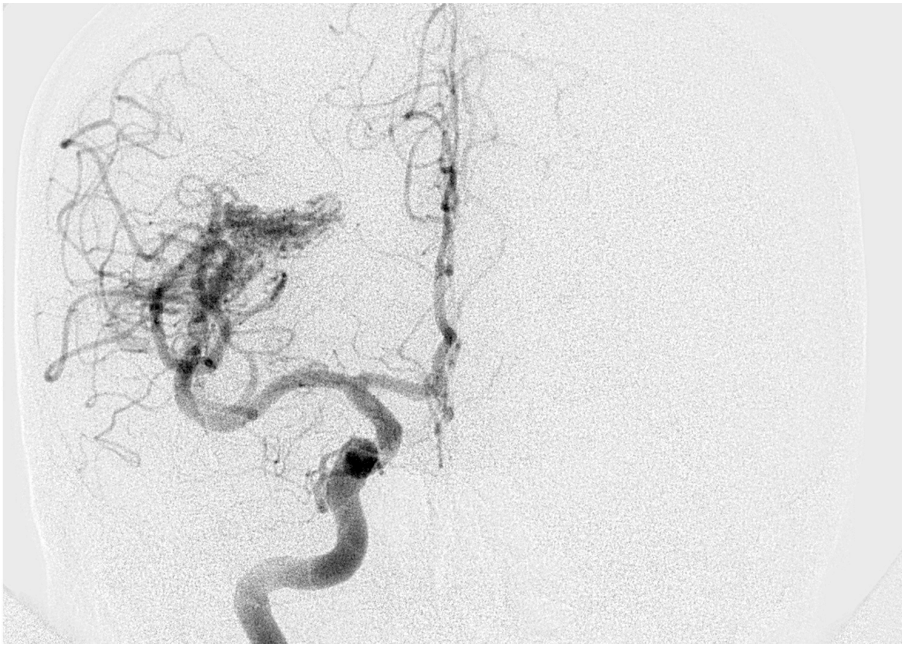


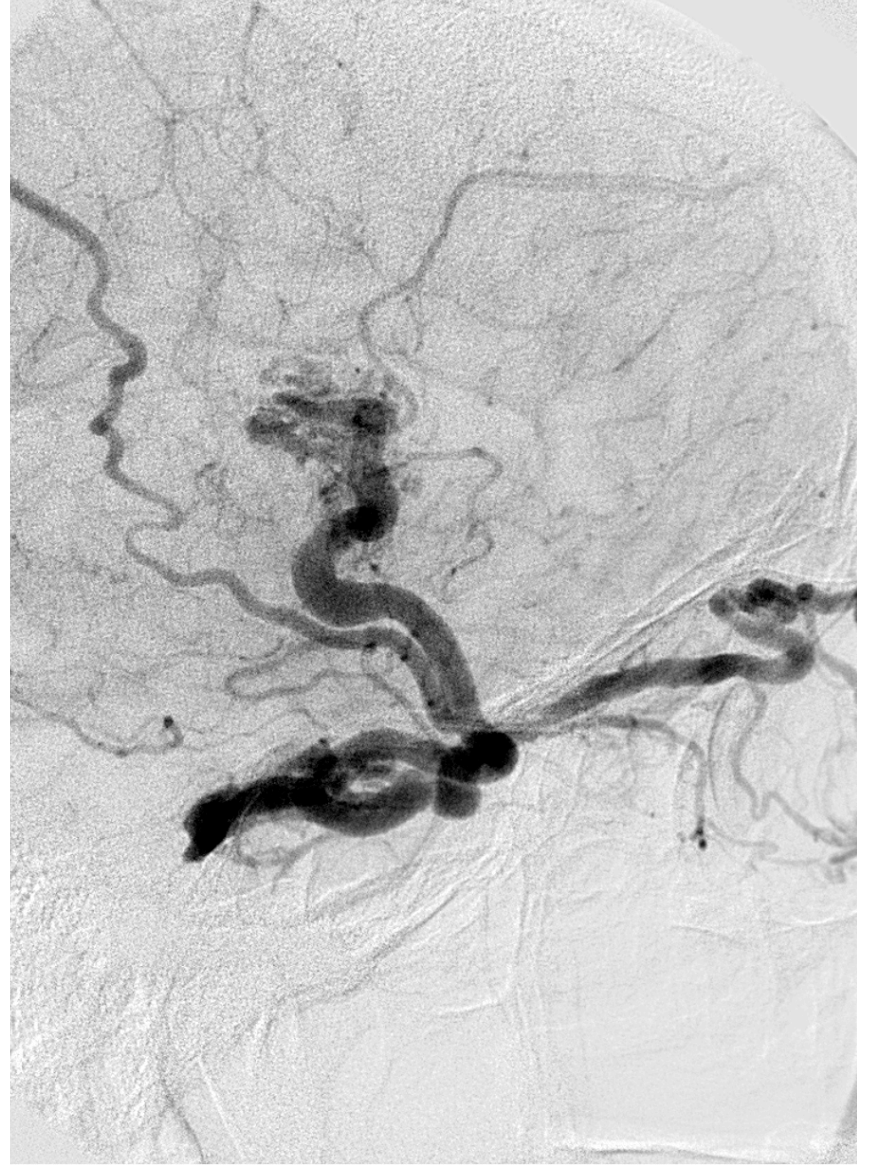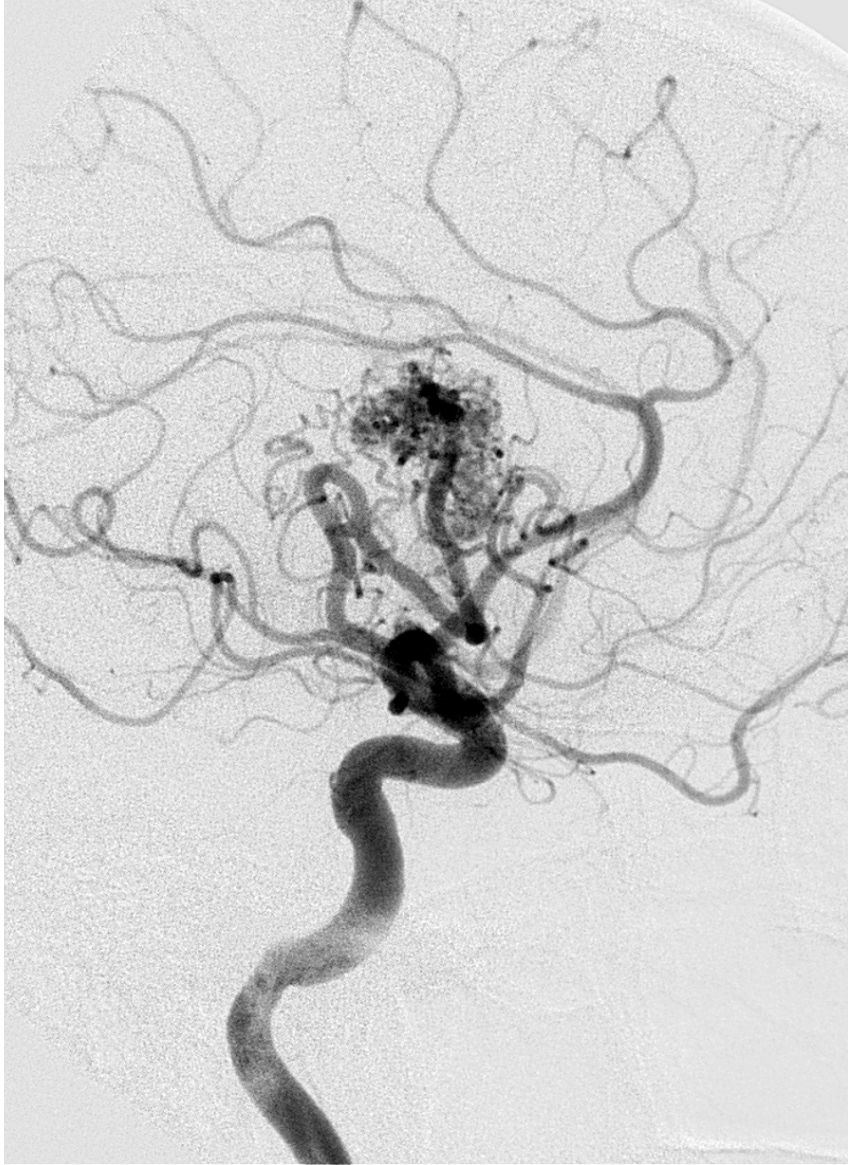
# Casi clinici MAV

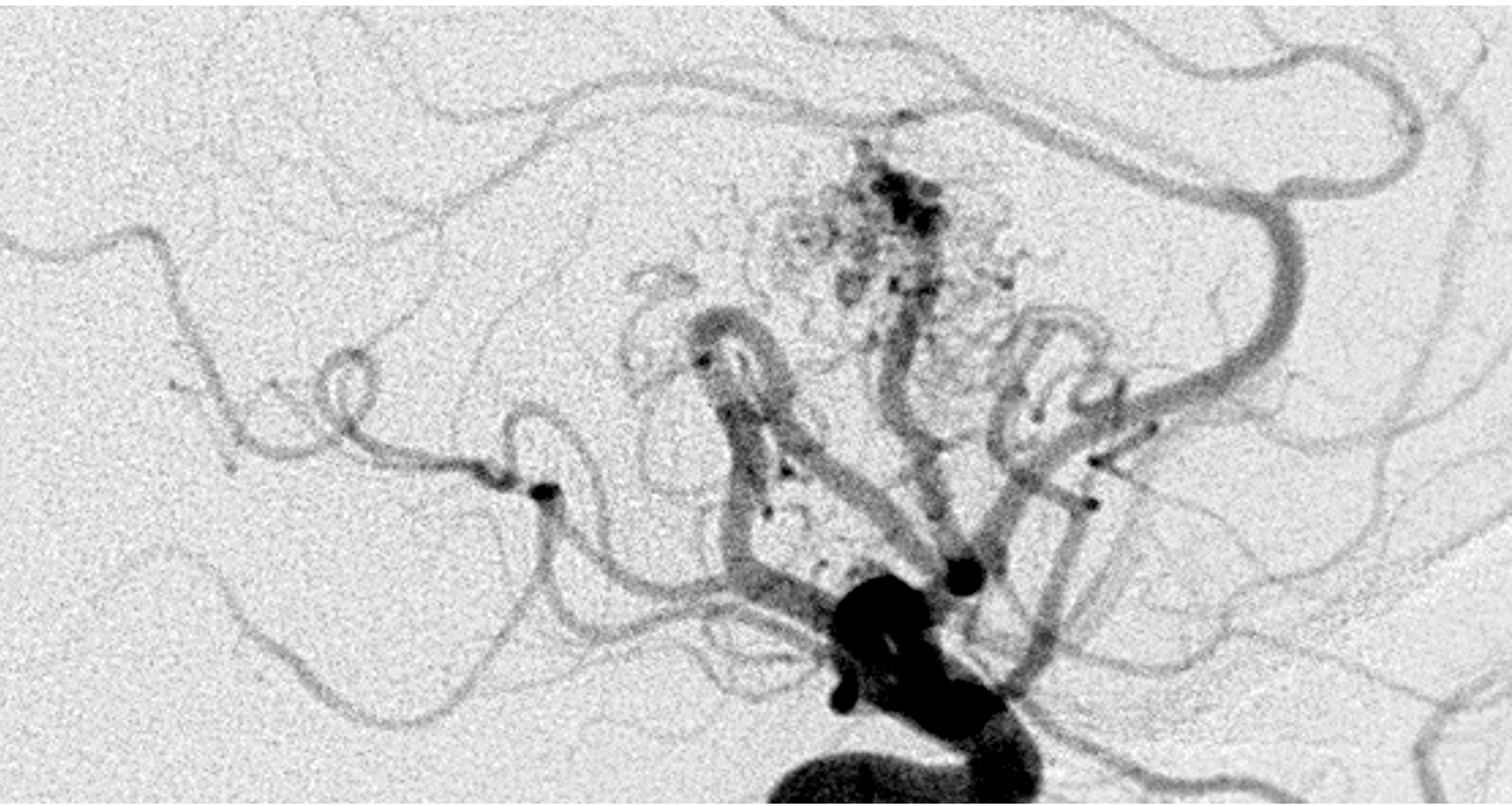
---













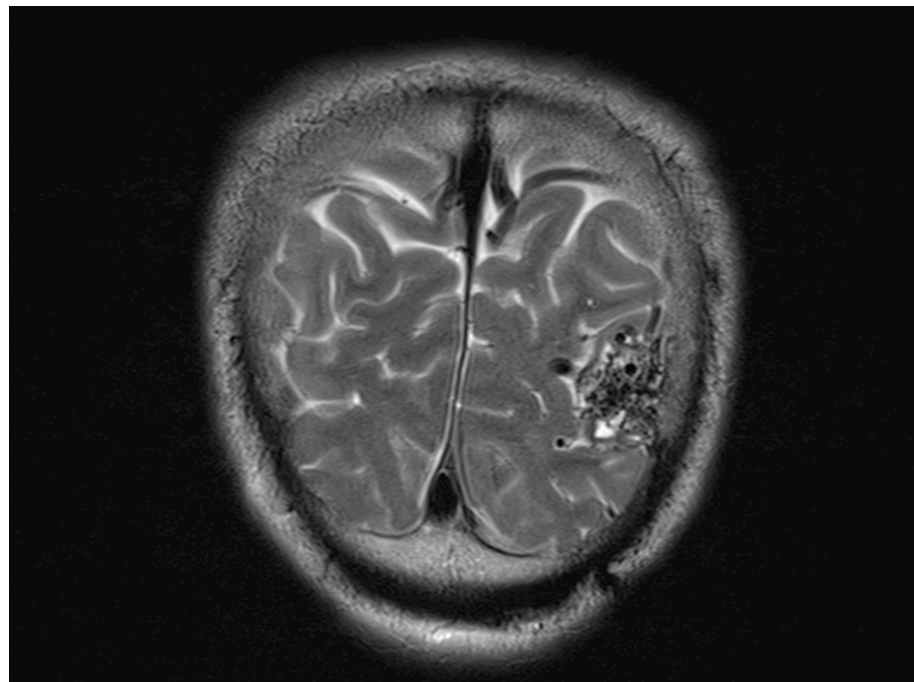
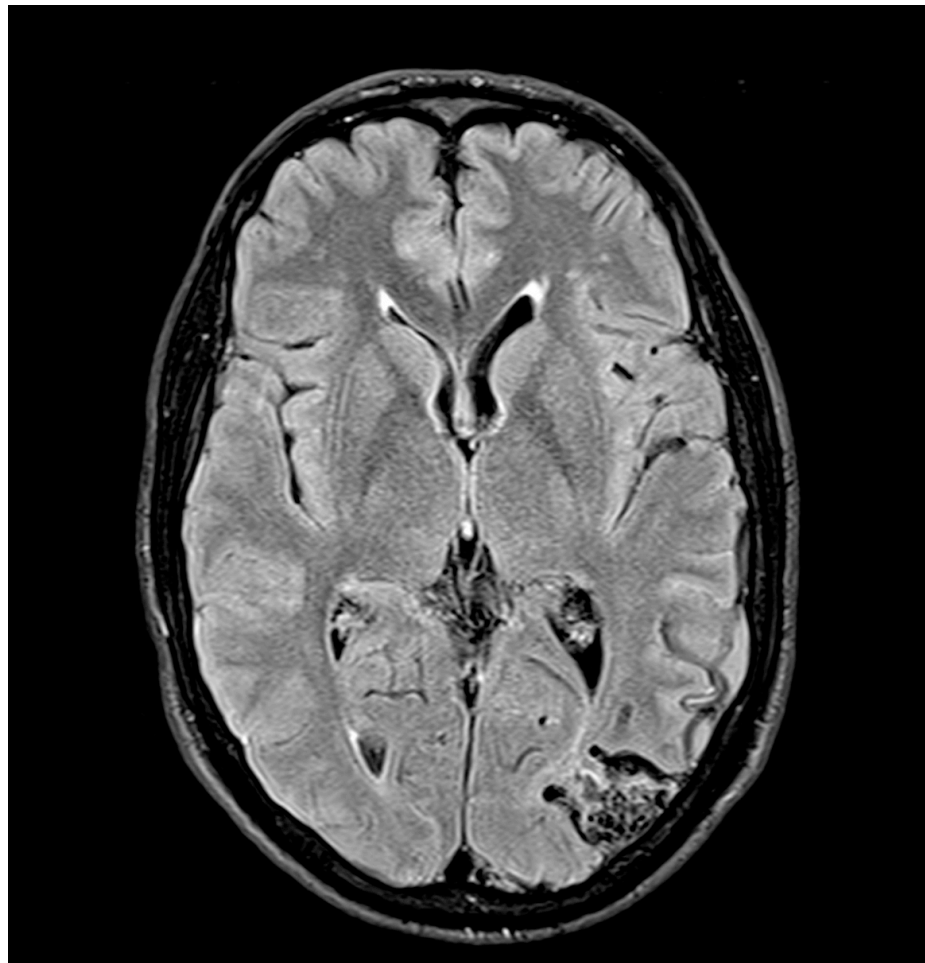
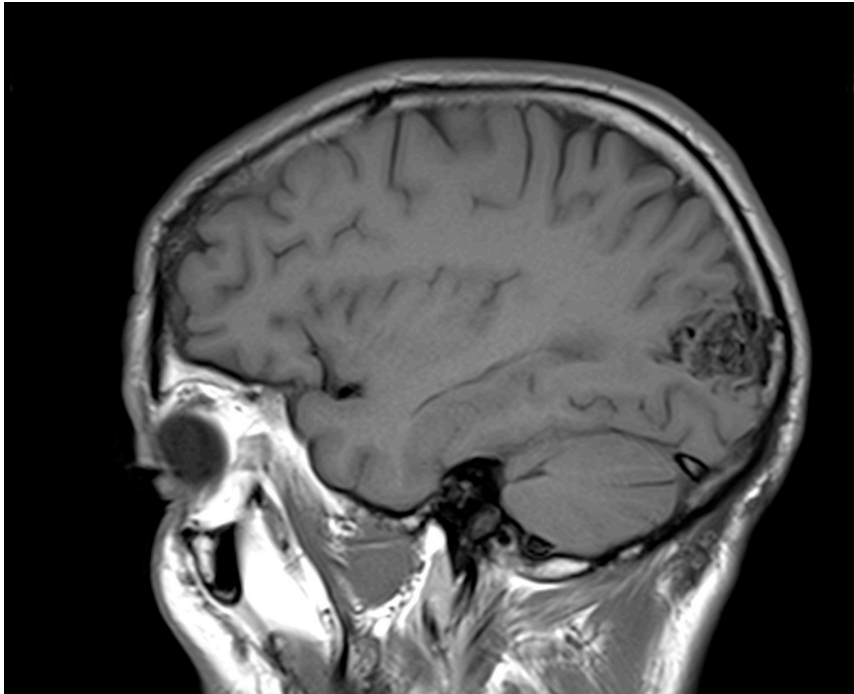


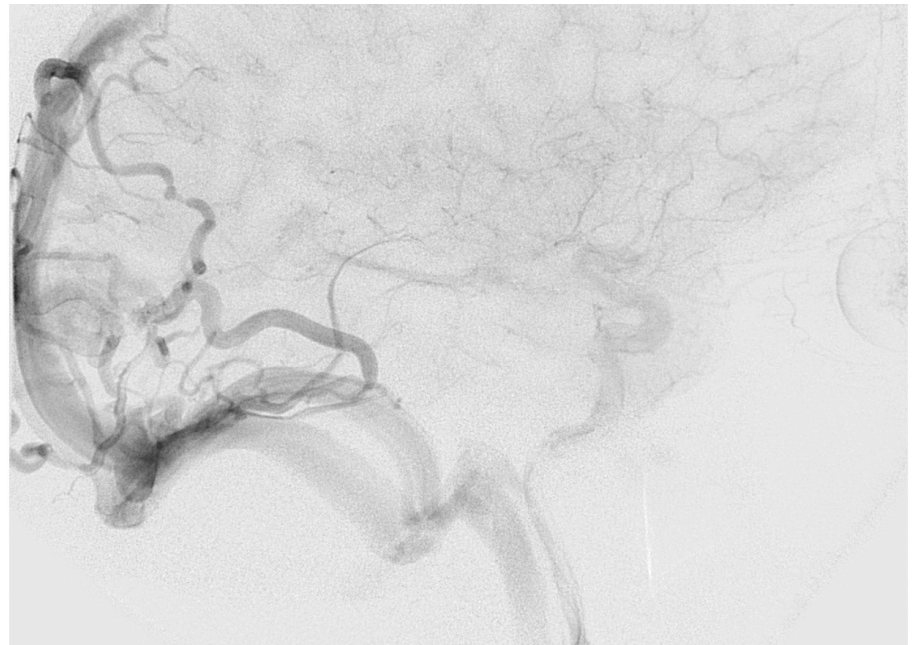
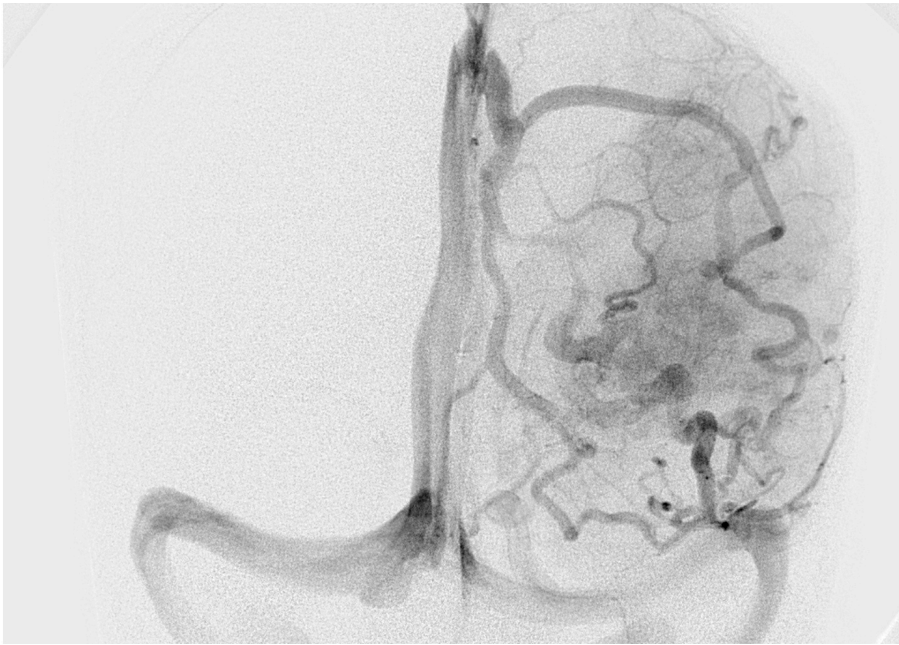
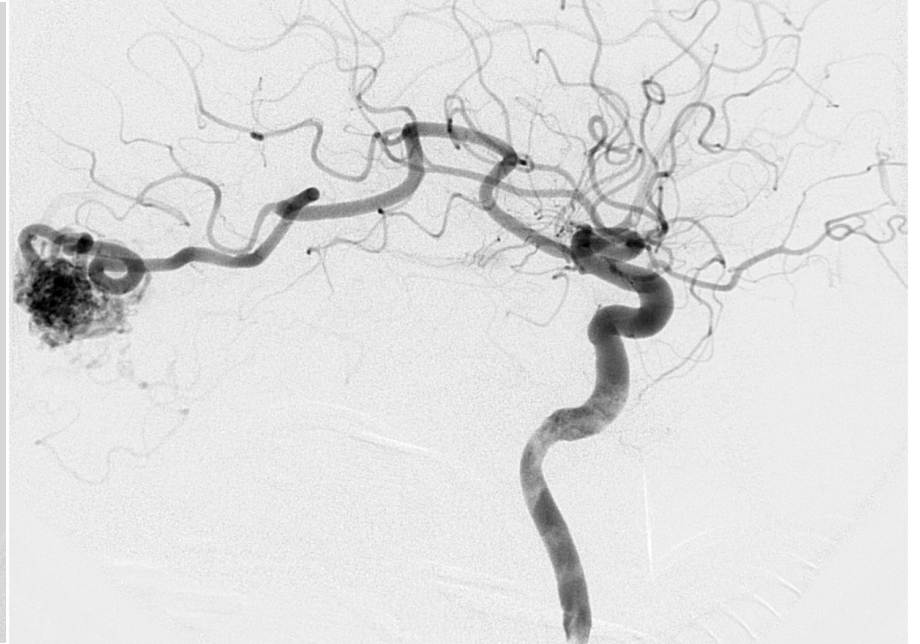
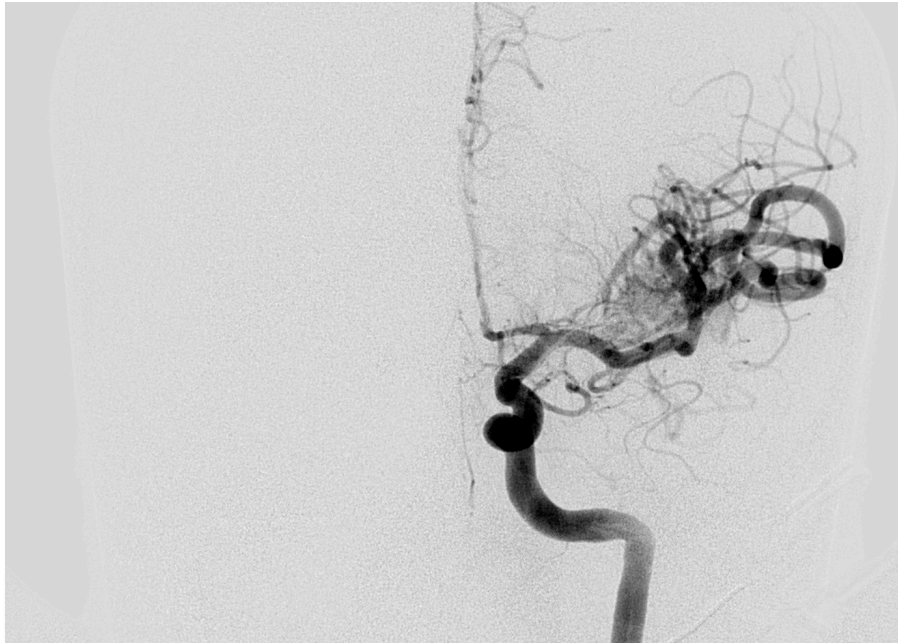




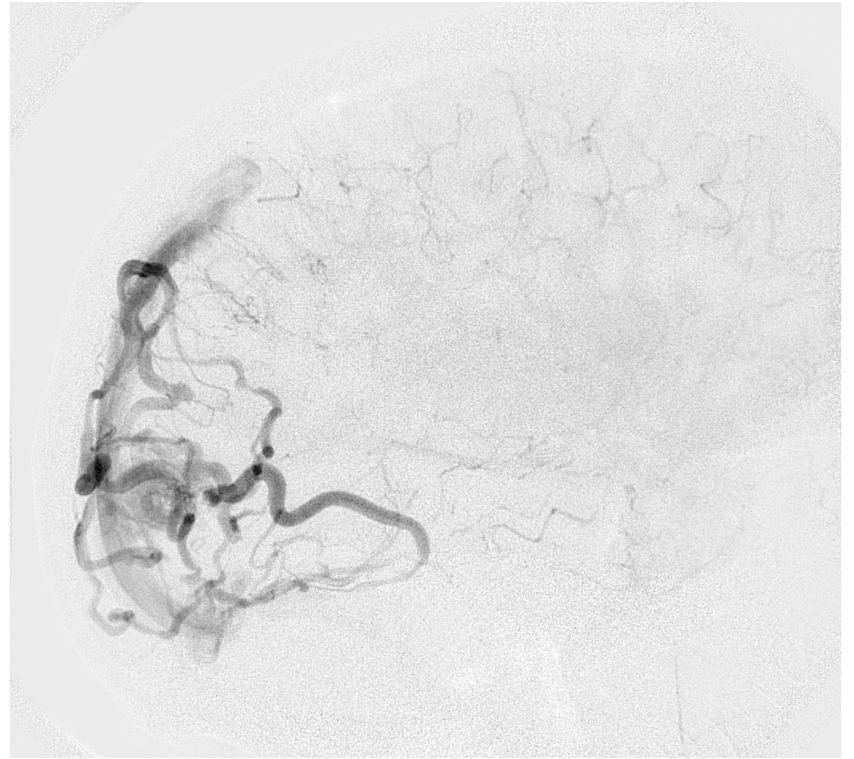
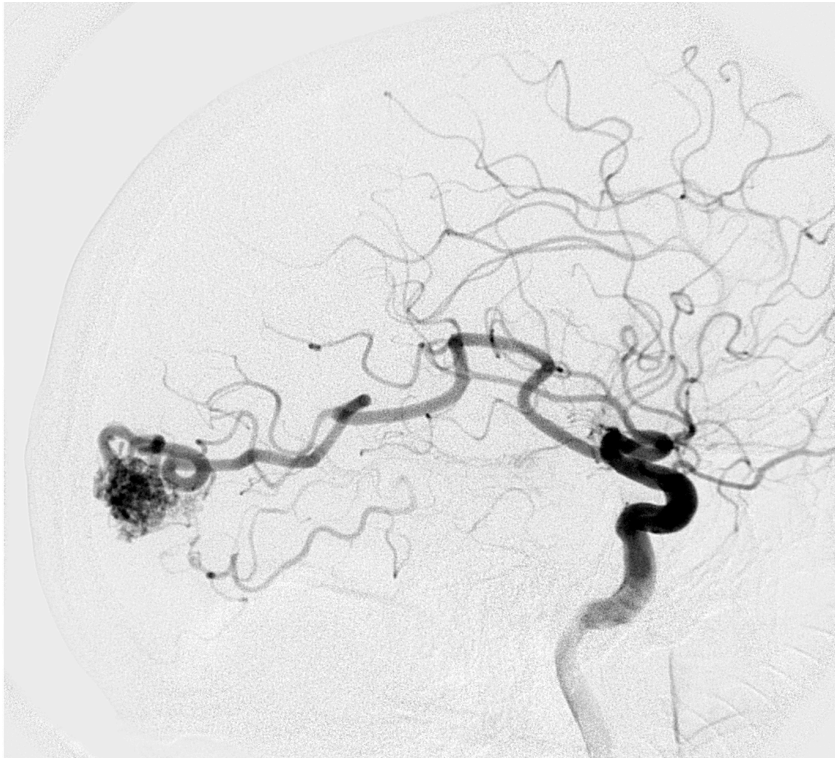


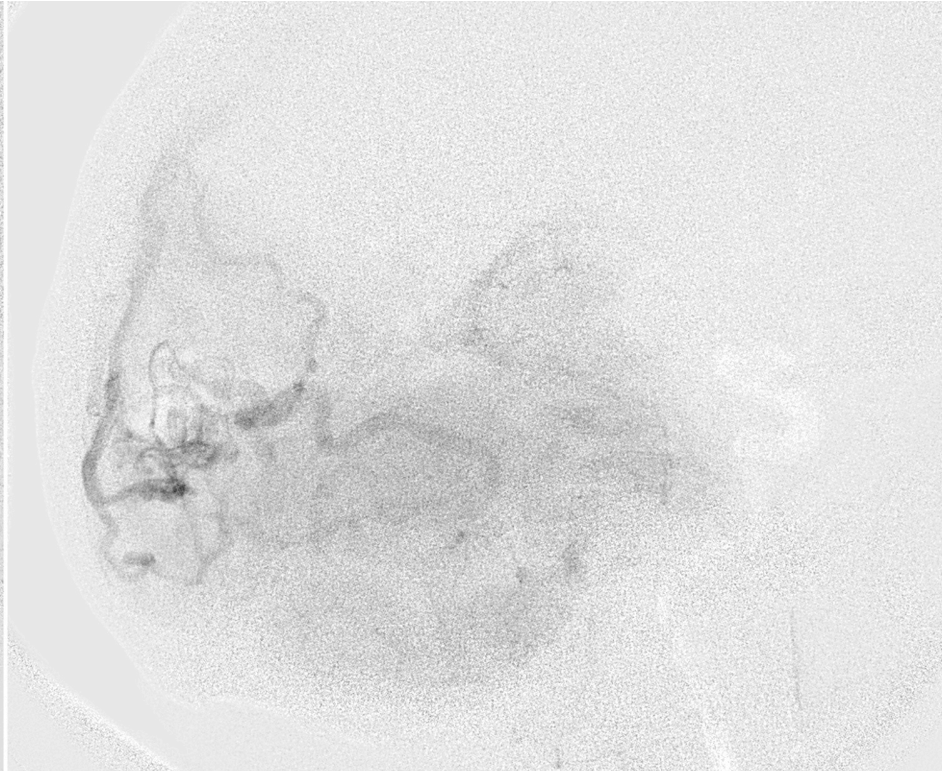
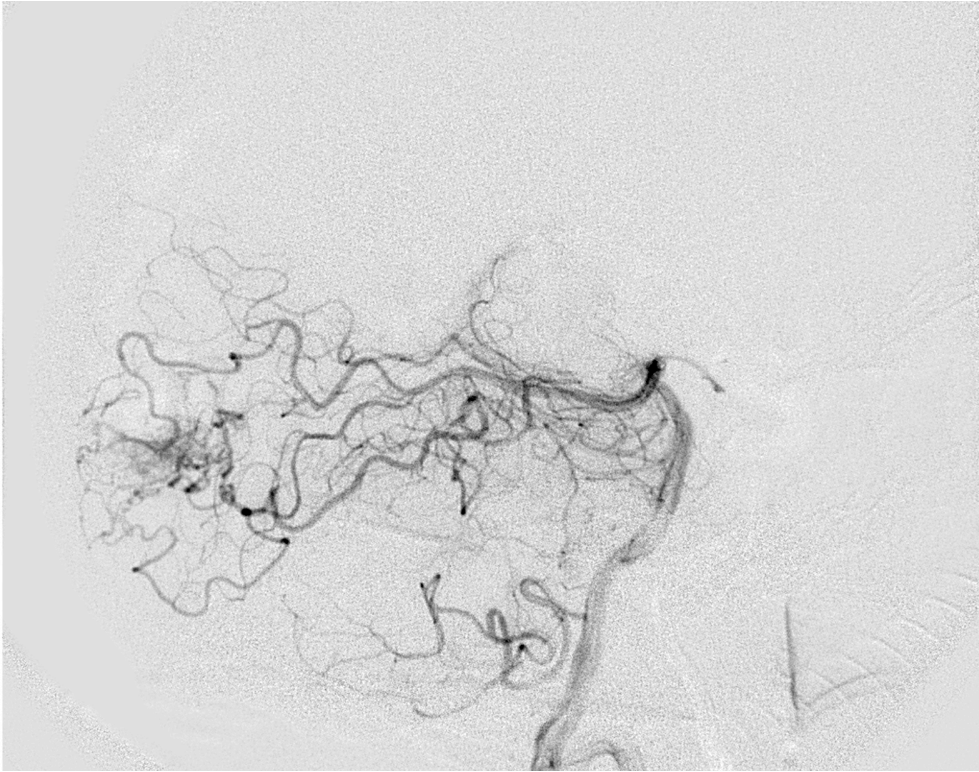


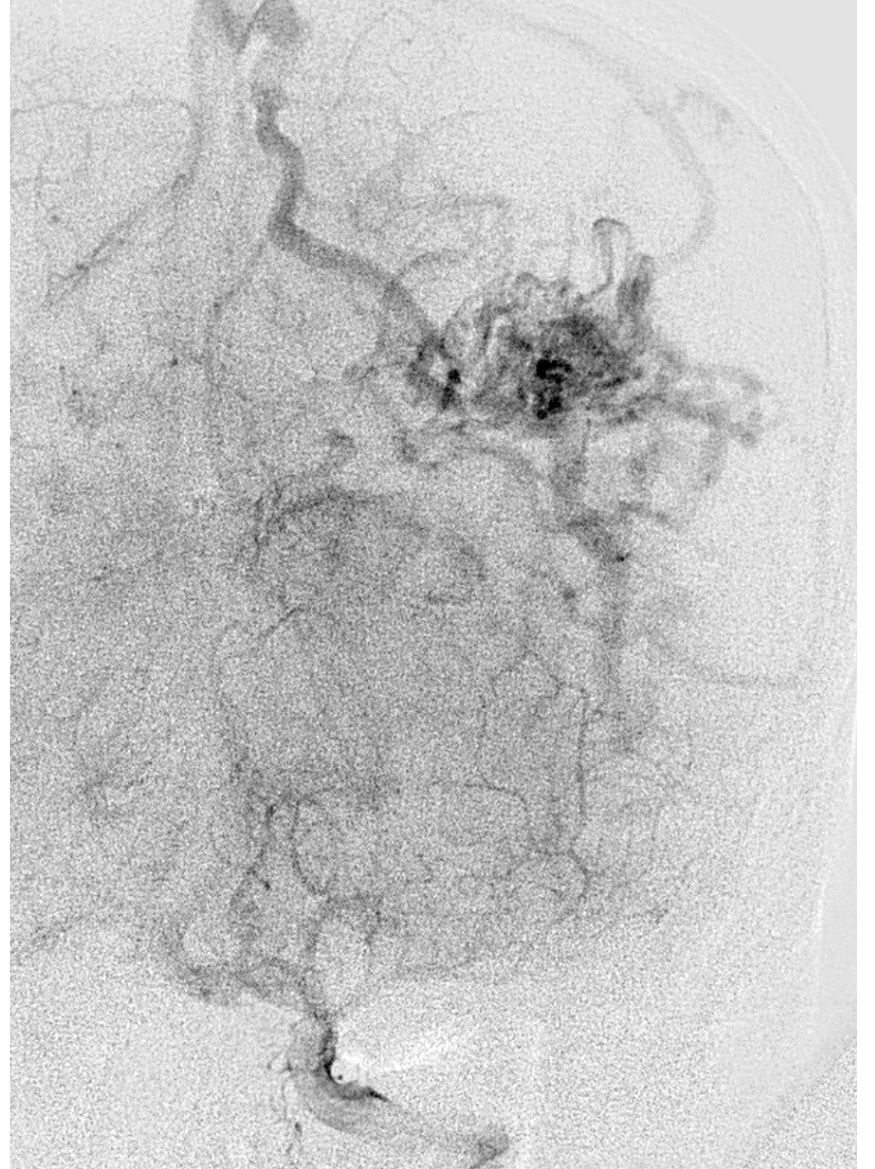
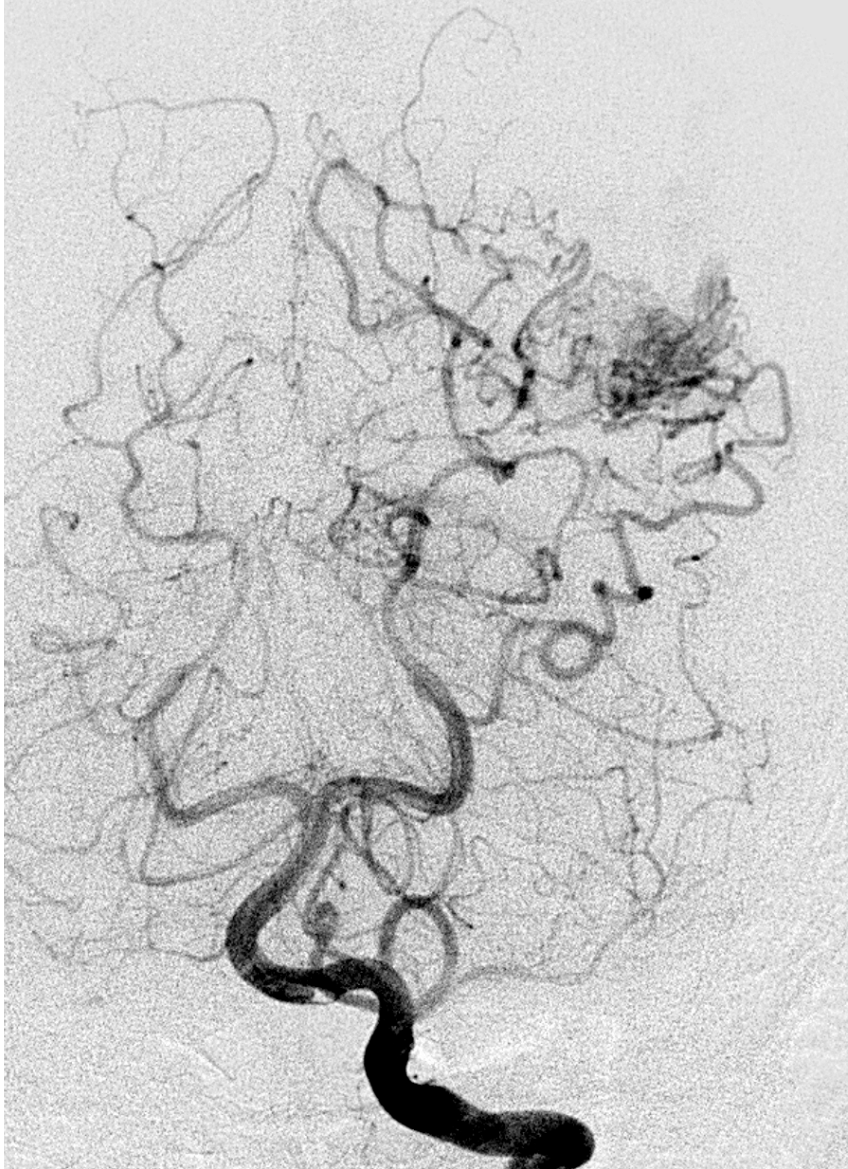












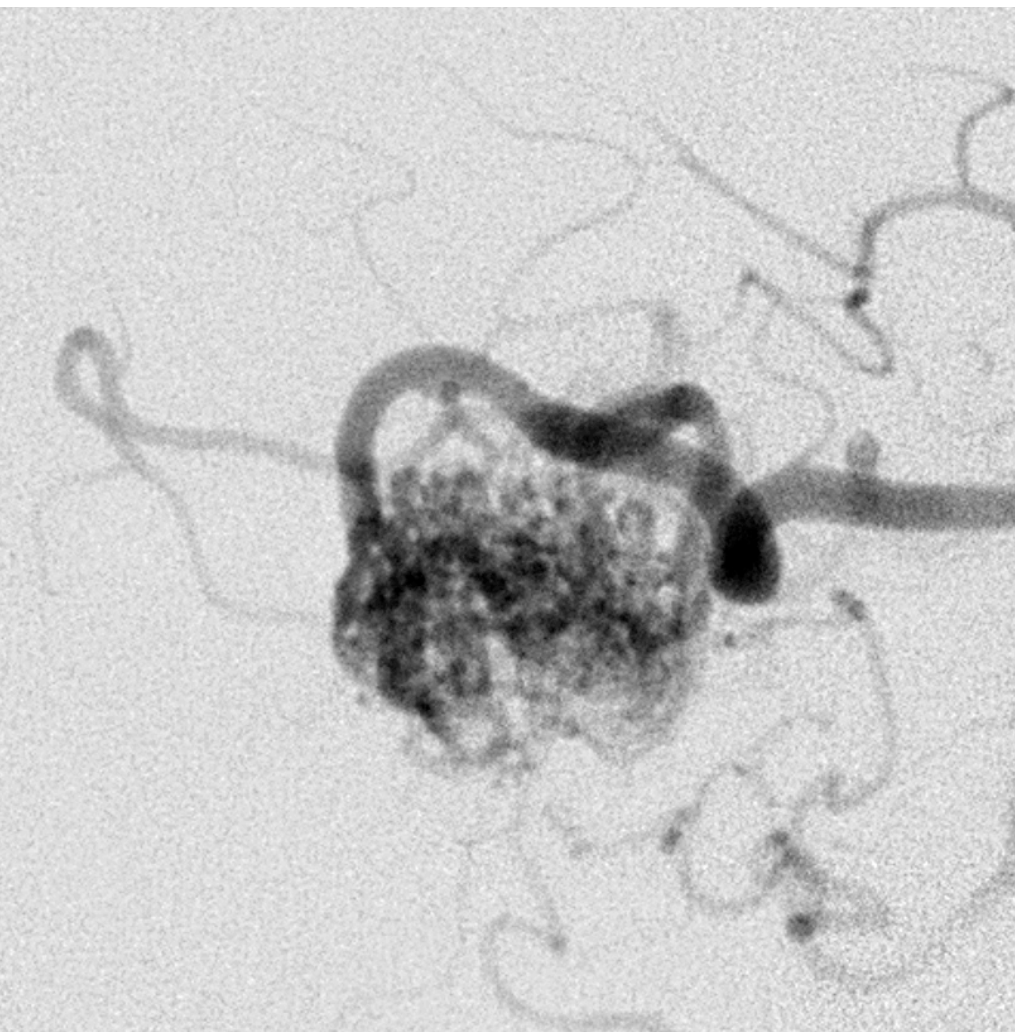
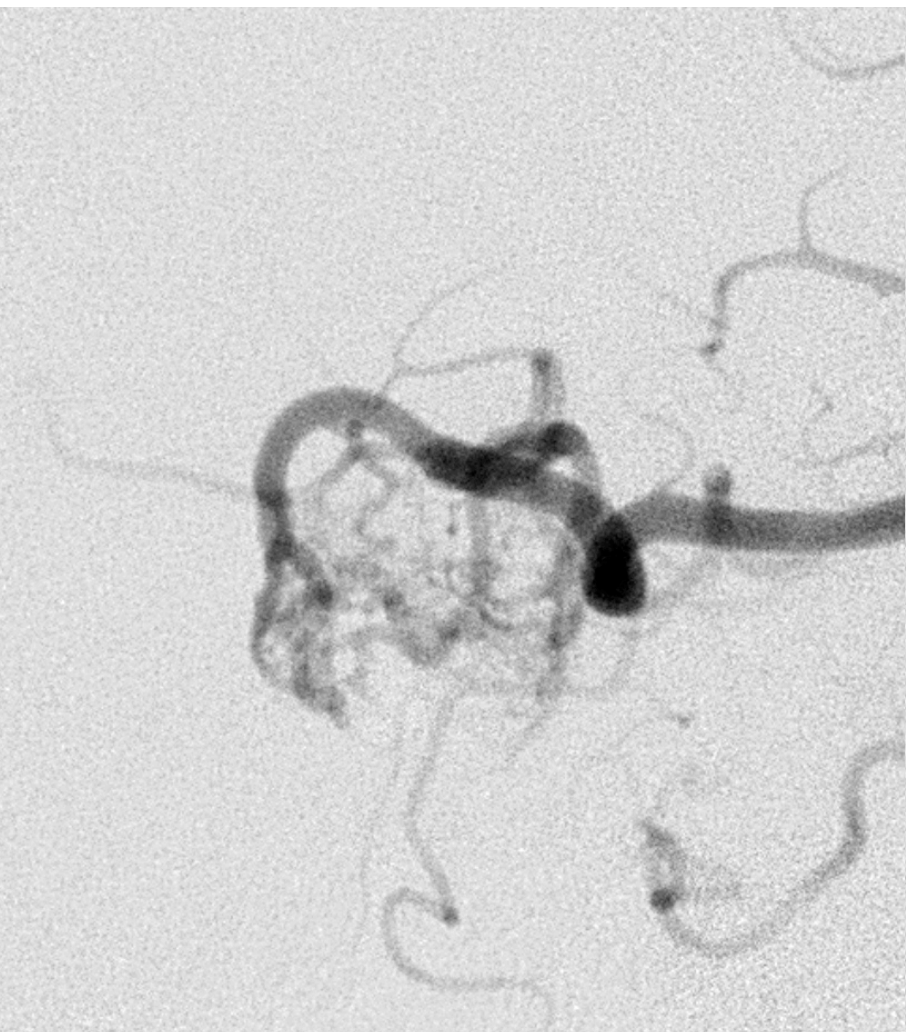








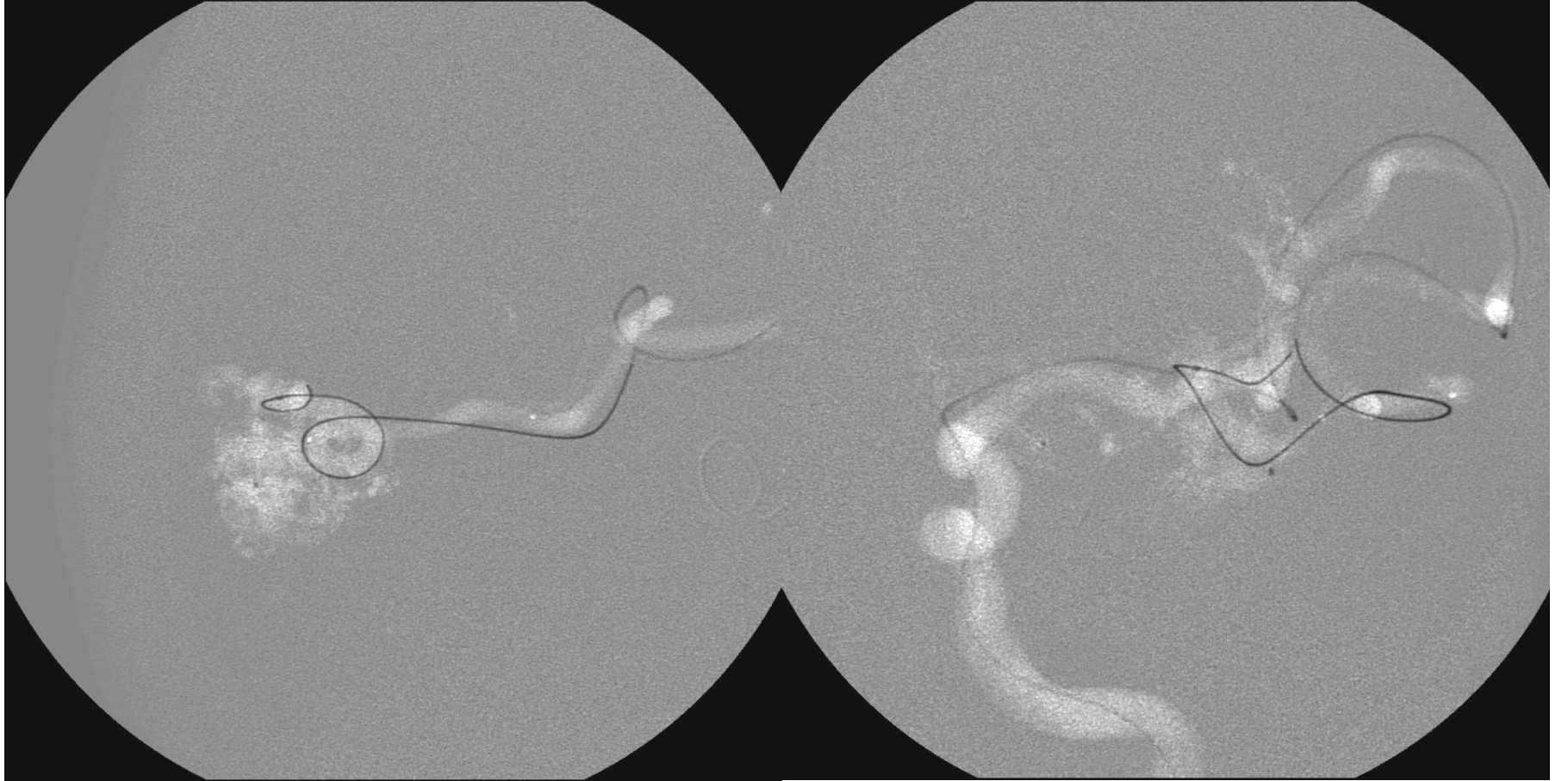



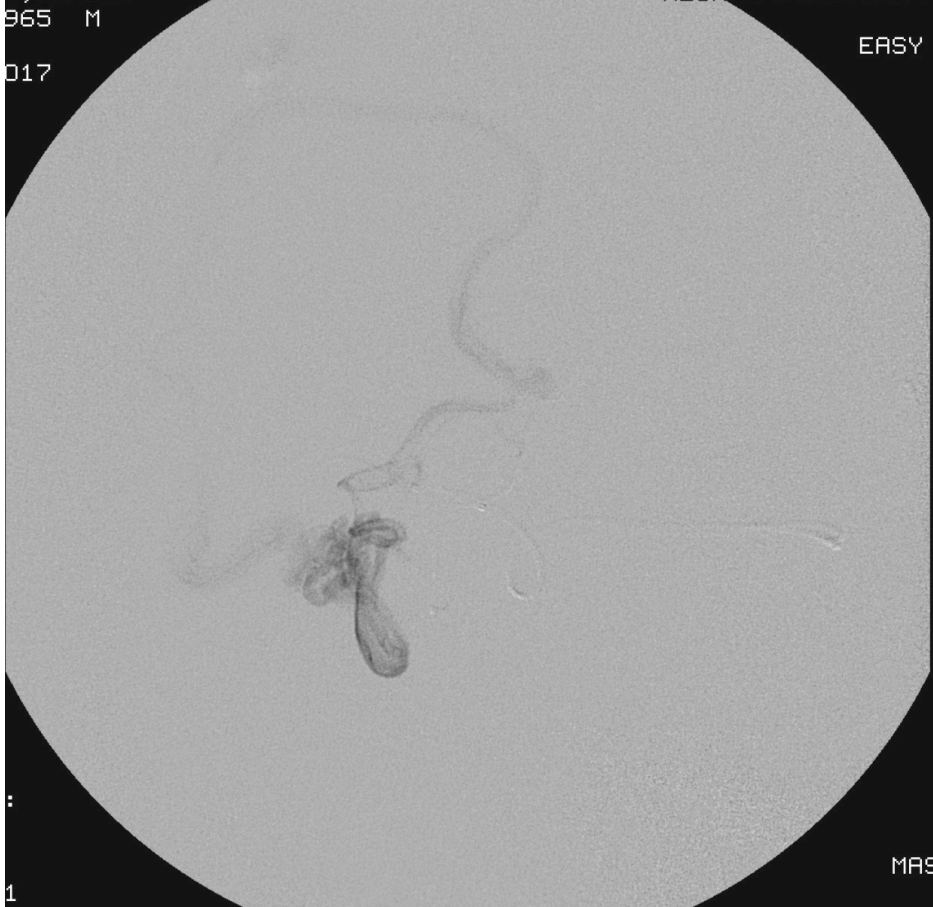




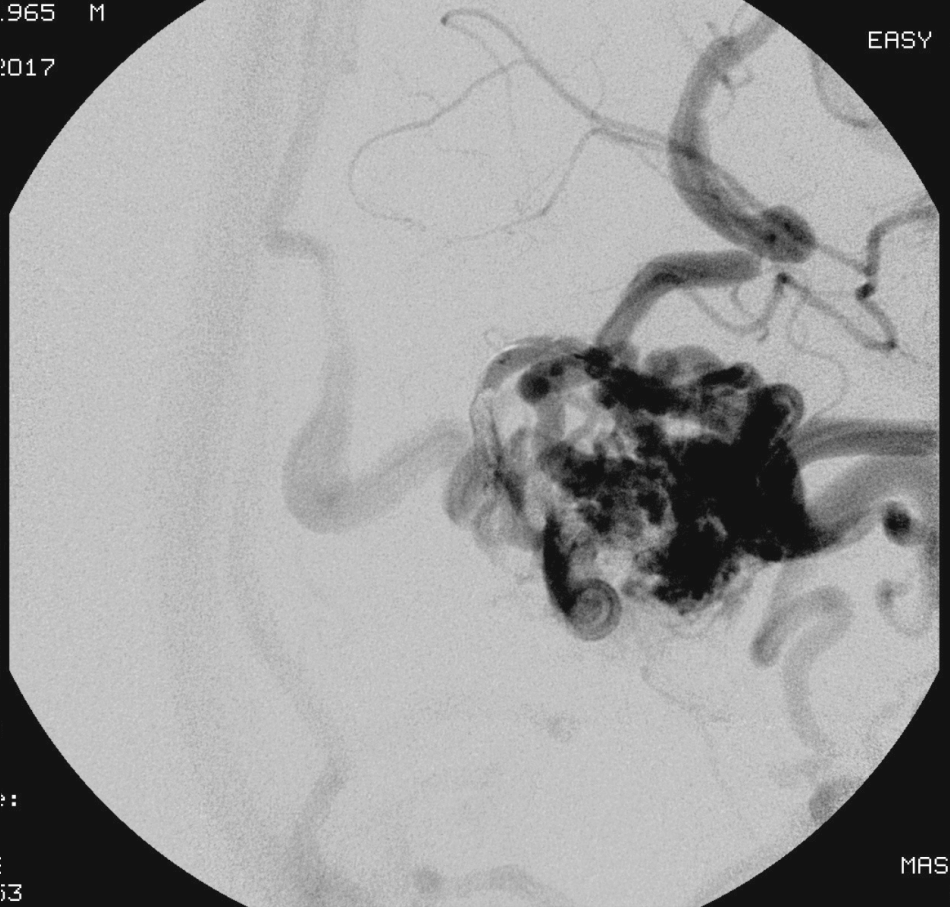




965 M  
017



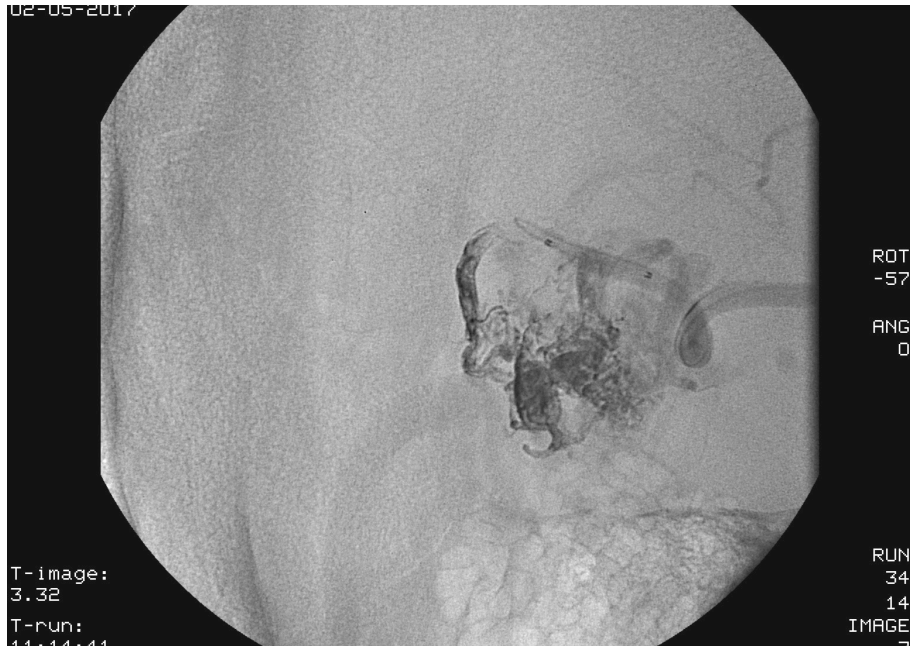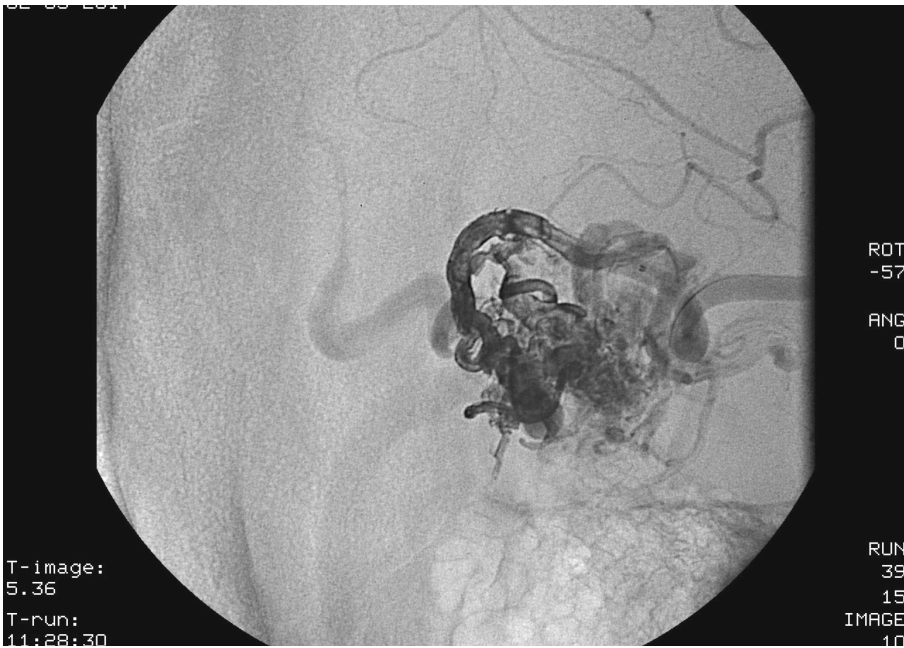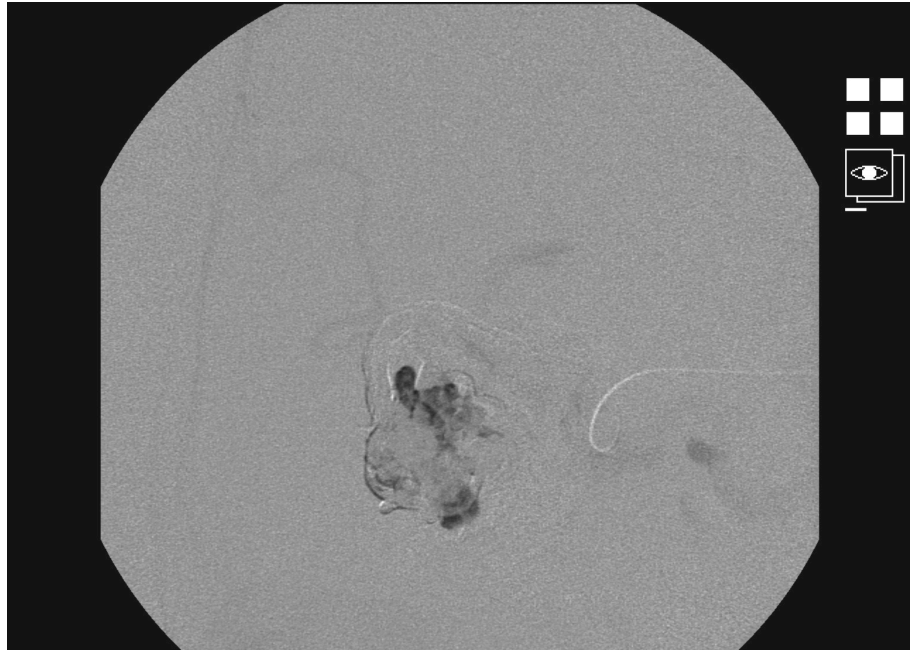
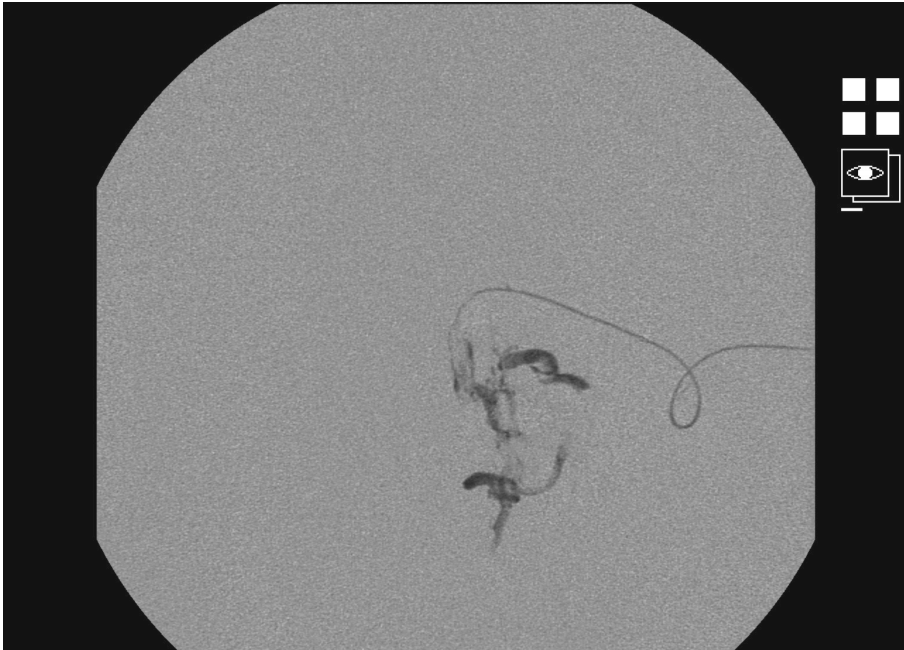
.965 M  
EASY 017




EASY

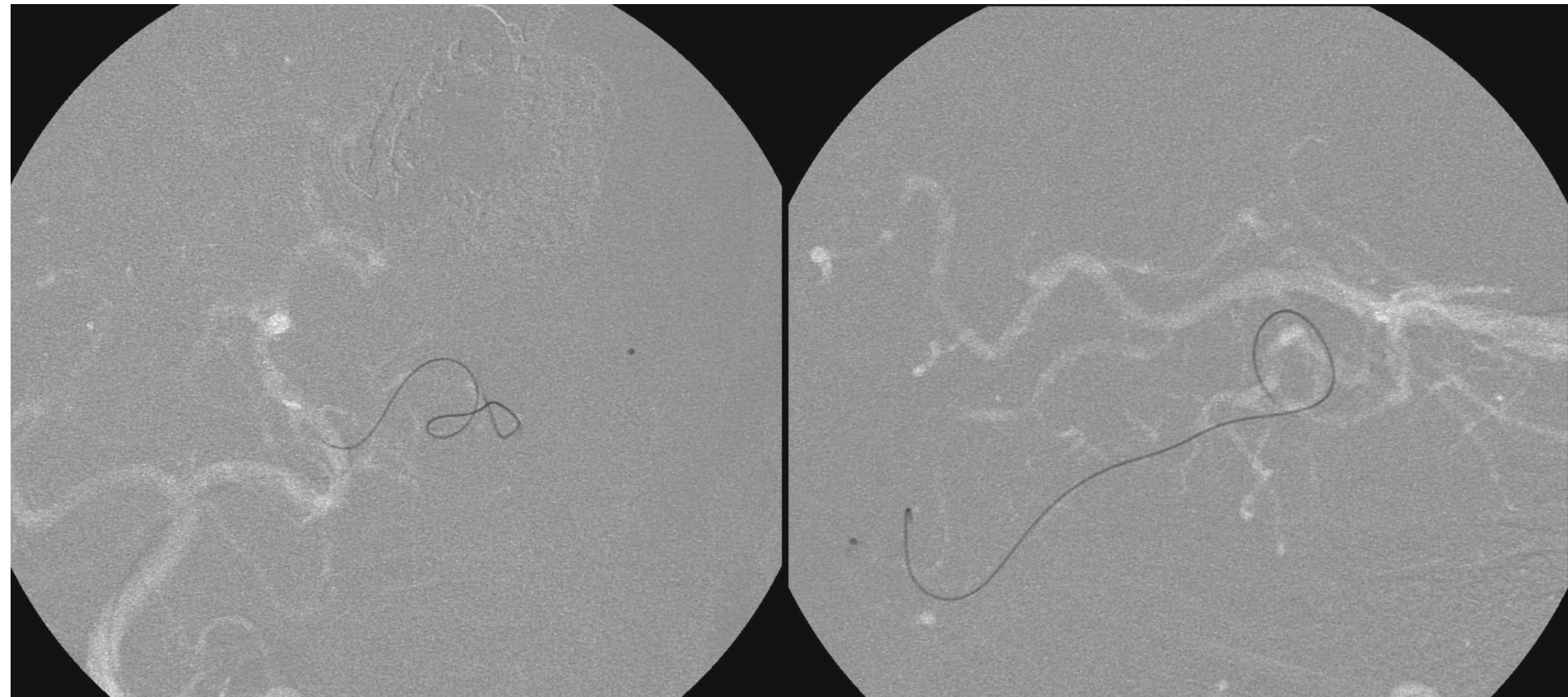
MAS  
13

MAS





## Approccio dal circolo posteriore





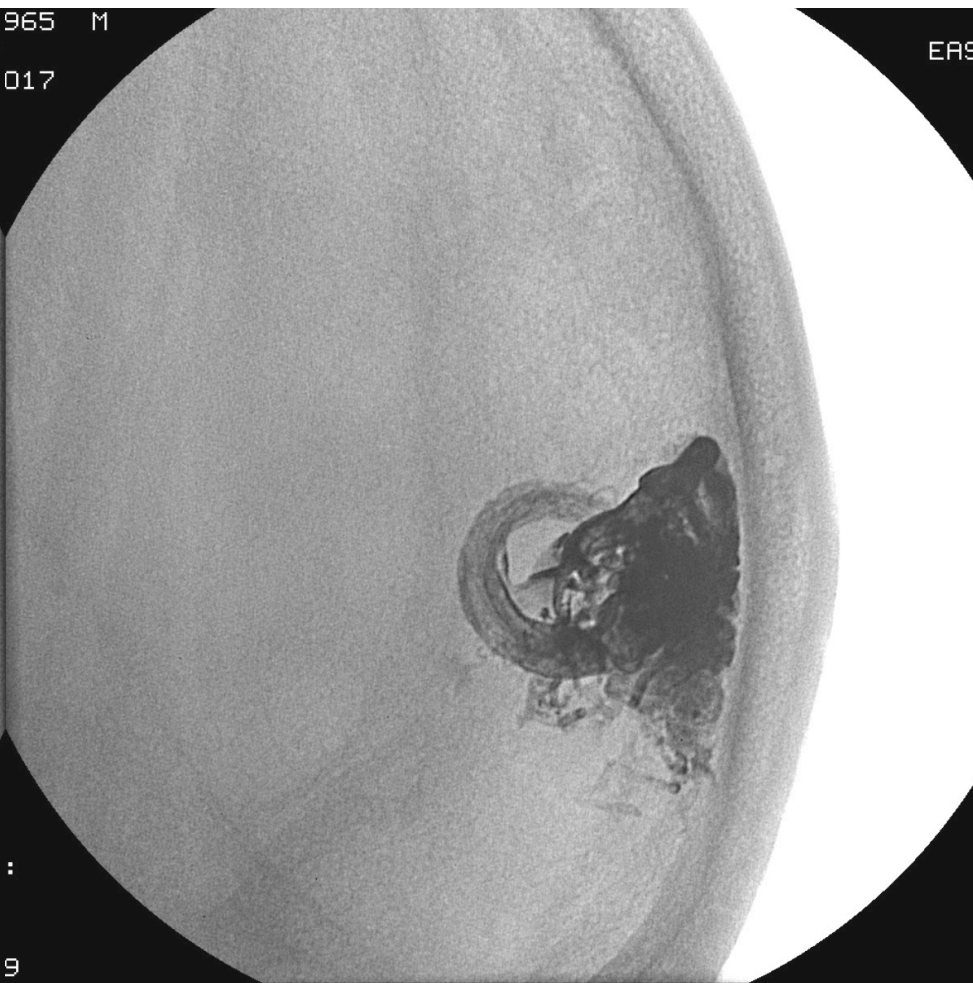
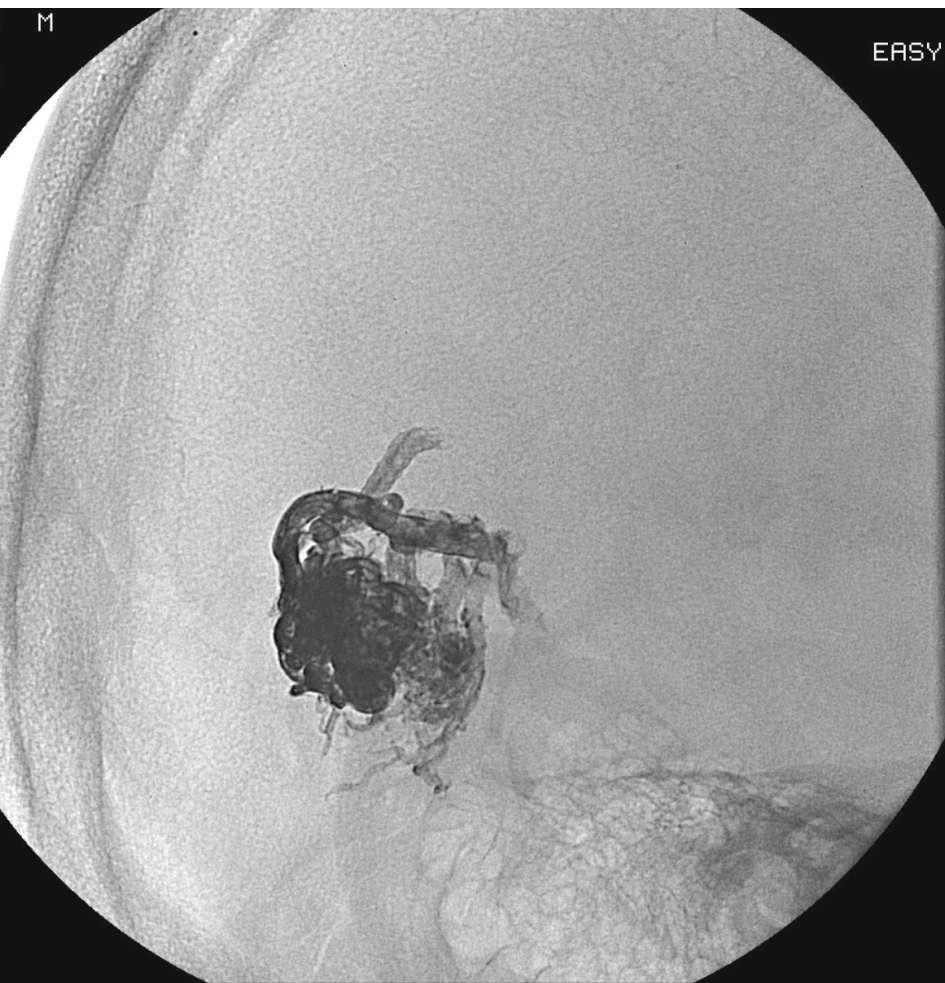










M

965 M  
EASY  
017

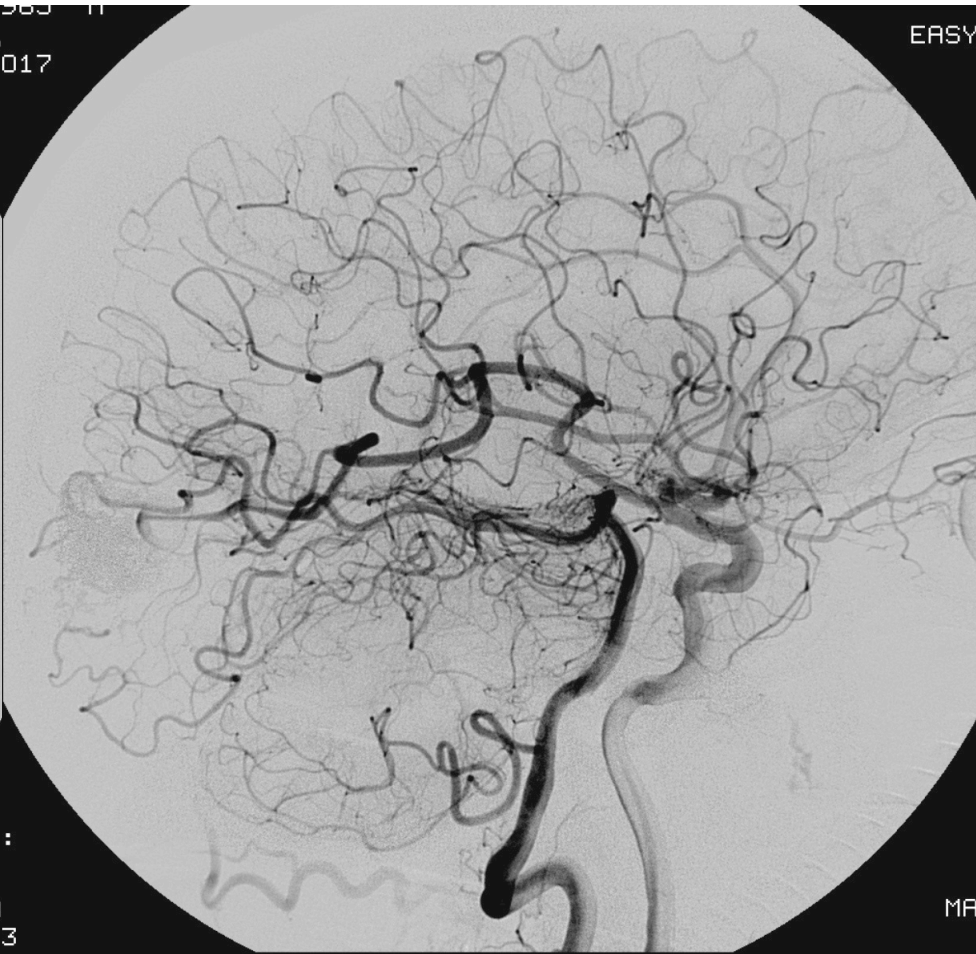
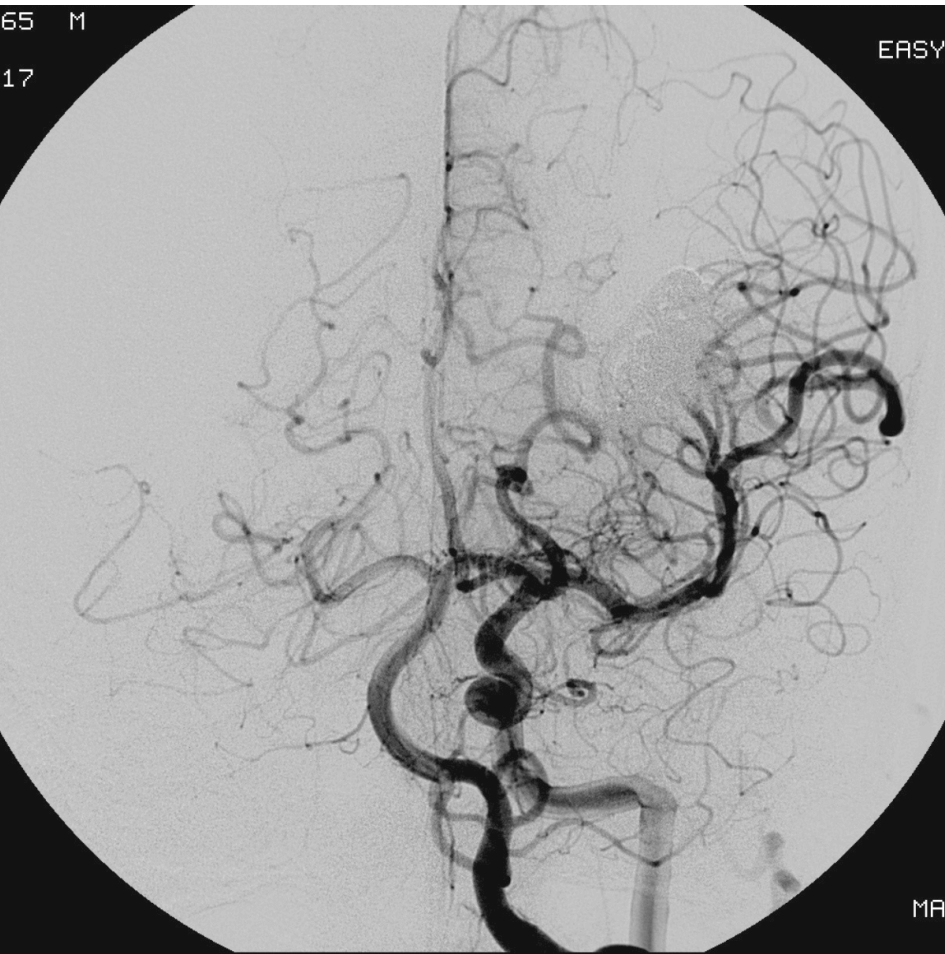EAS

9

65 M  
17

583 11  
EASY 017

EASY



MA  
3

MA